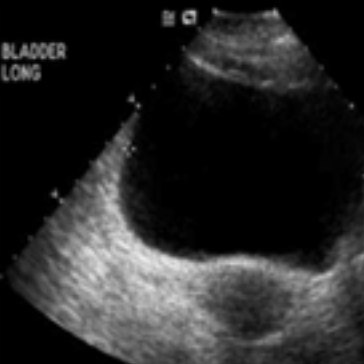
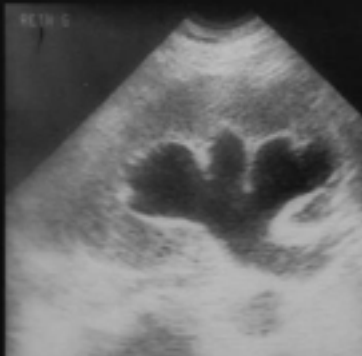
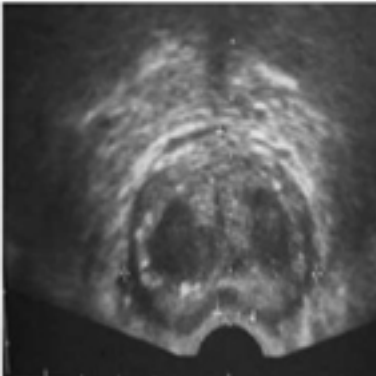
BLADDER
LONG

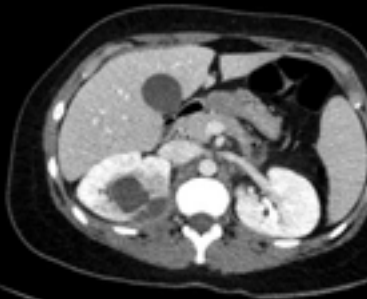11 C



RETN 5

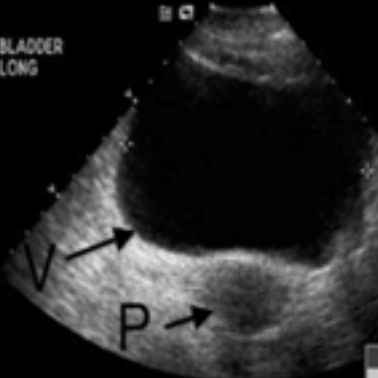






BLADDER
LONG

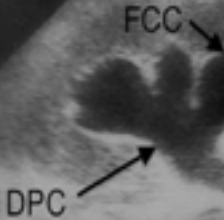11 C

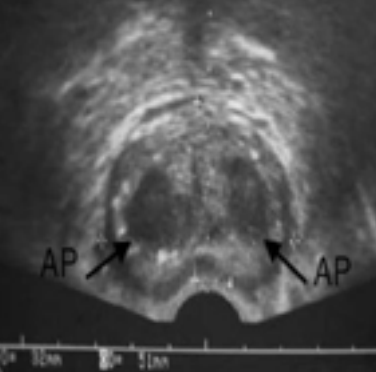


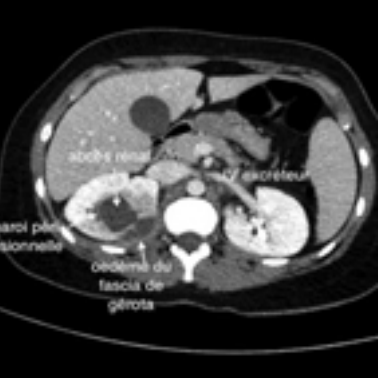V

P

RETR 5





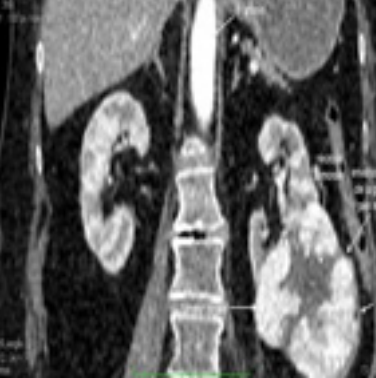

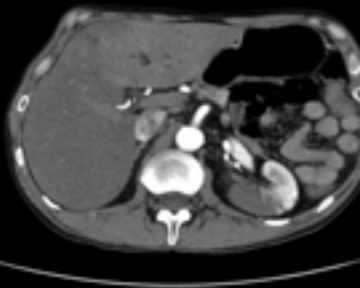
abcès rénal

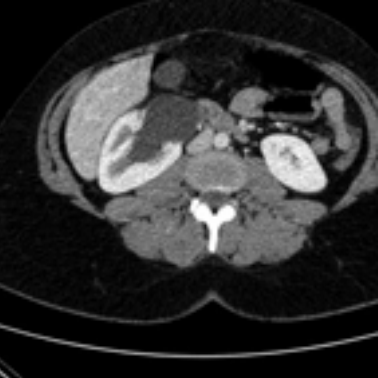
cy excréteur

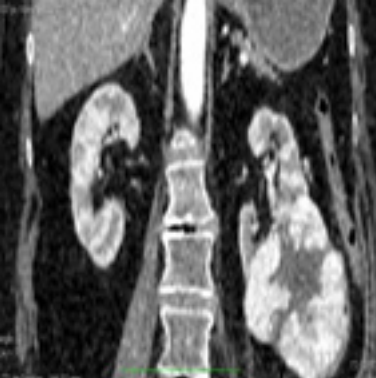carot ple
tionnelle

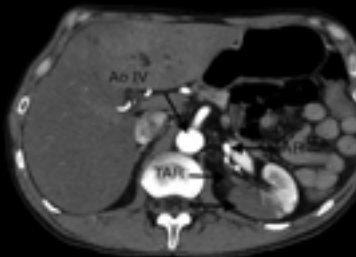
oedème du
fascia de
périto

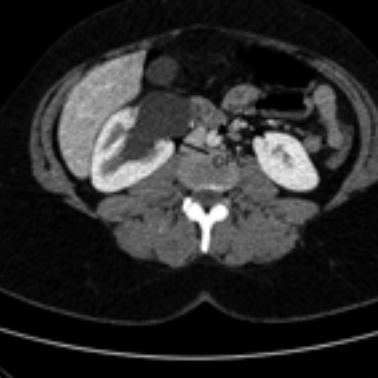

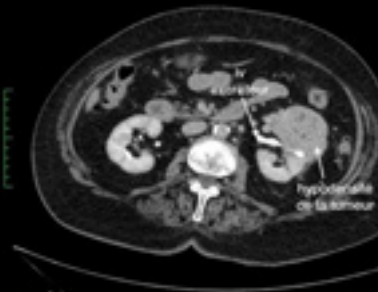







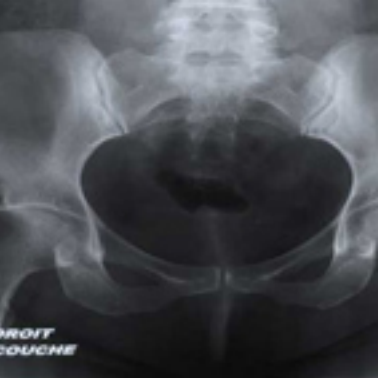




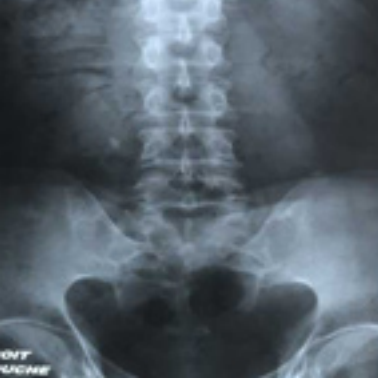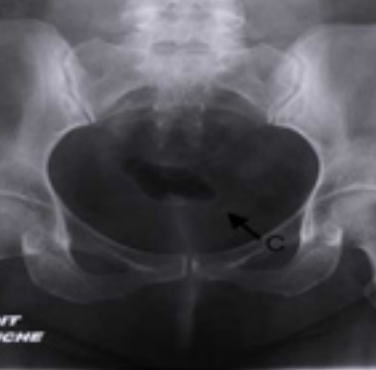COUCHE

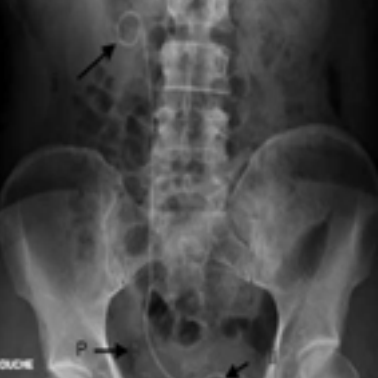


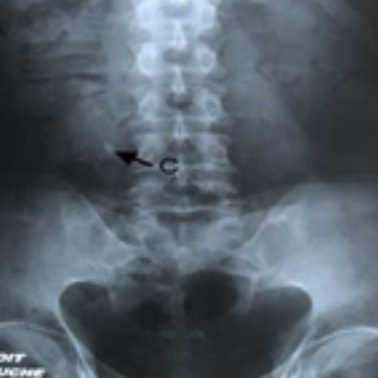
PROFT
COUCHE

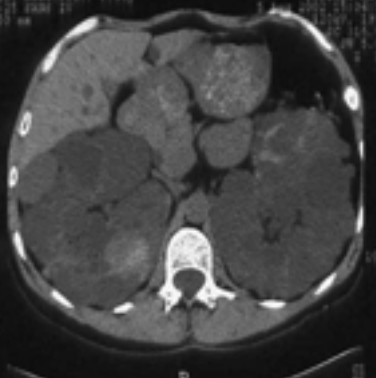

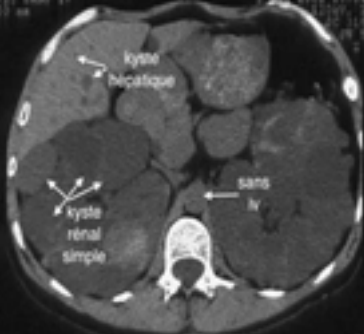






ONT
LUCASF

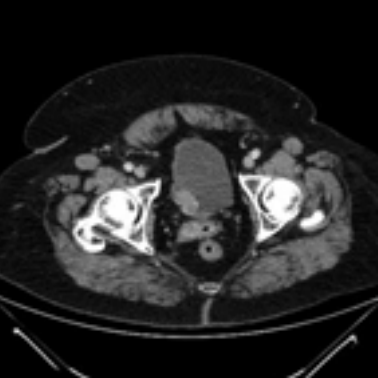


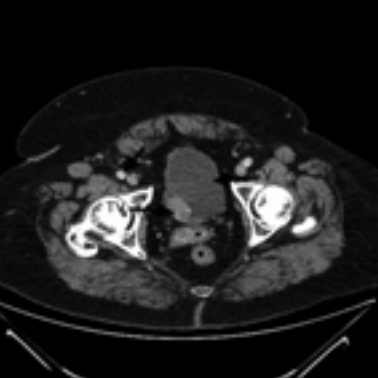


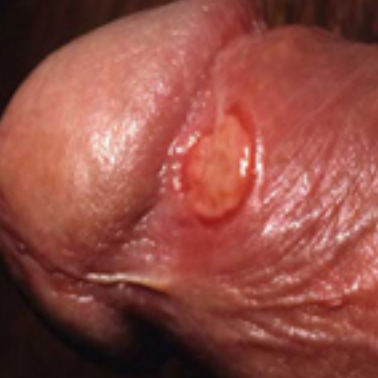kyste
hépatique

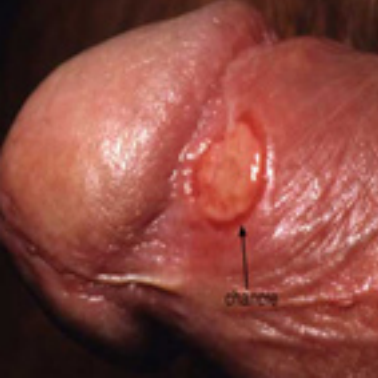kyste
rénal
simple

sang
iv

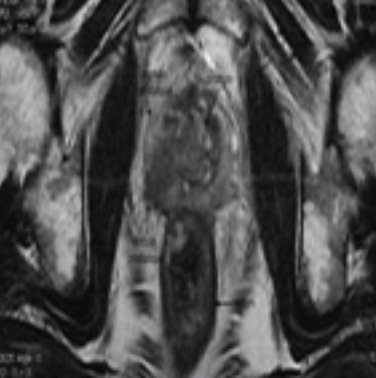

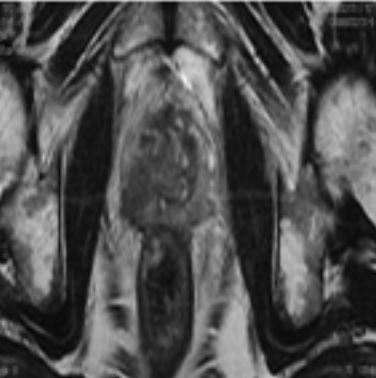


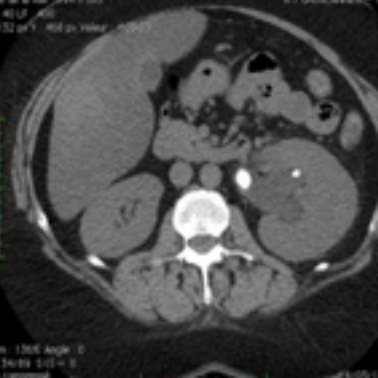




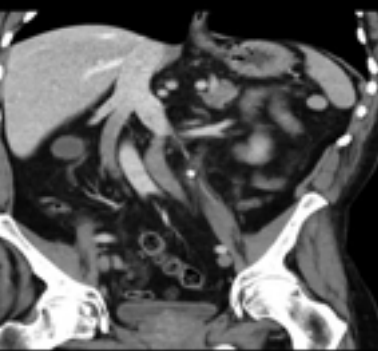
chancro







120kV Angle 0
1400 1-1-0
Lumbar

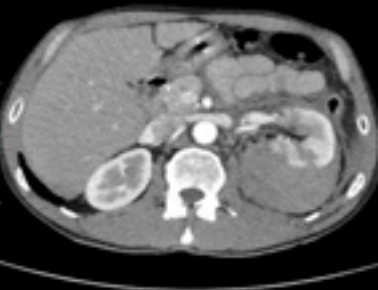

Age la vue : 581 x 351

ALCOFEN 110-4634mm - A

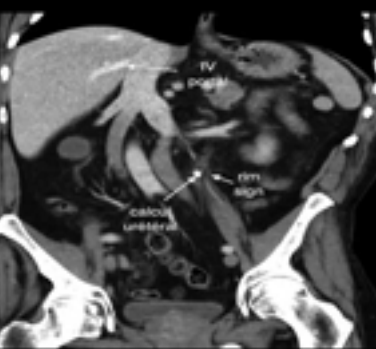50 LF : 350

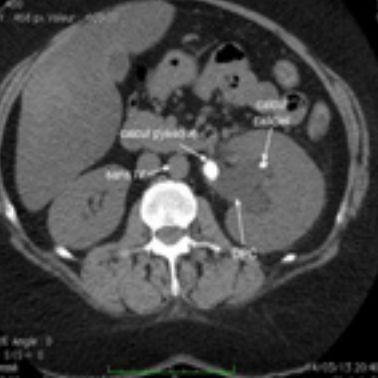
3 ps Y : 495 ps Valeur : -416.00



1155 Angle : 0

06x76 15 - 0

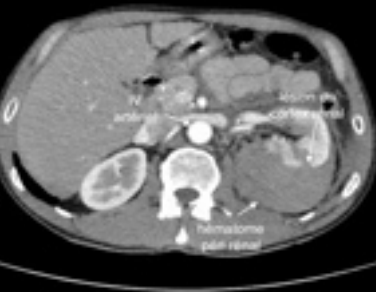



Angle: 0
1/1 = 1
mm

14-05-13 20:40

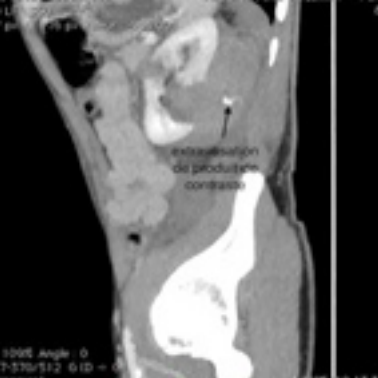
0 LF : 350
px Y : 495 px Valor : -816.00



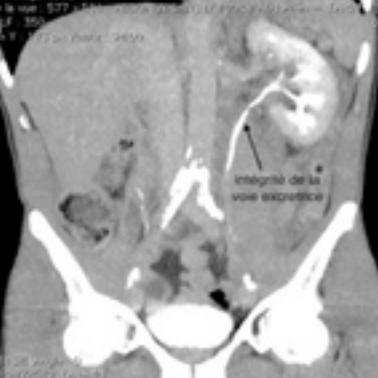1155 Angle : 0
676 15 = 0
emboged

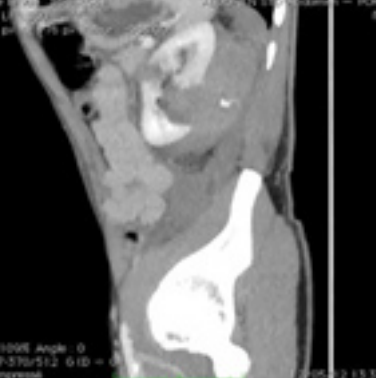
12/05/10

12/05/10



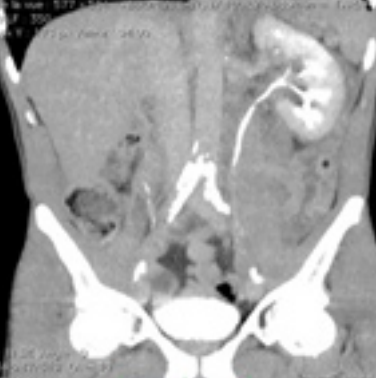extravasation
de produit de
contraste

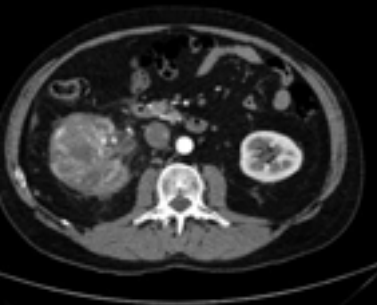


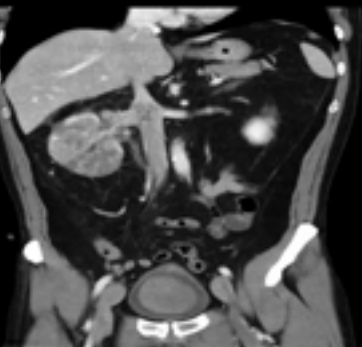


100% Angle: 0
7-376r51.2 610 - 0
revised

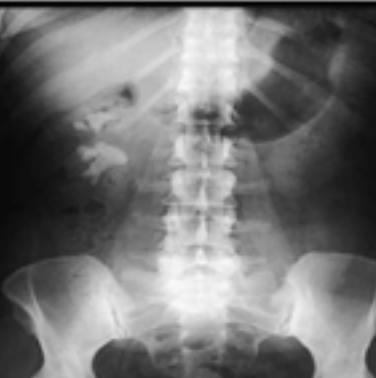205-02153

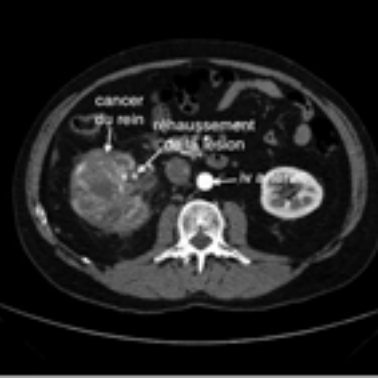







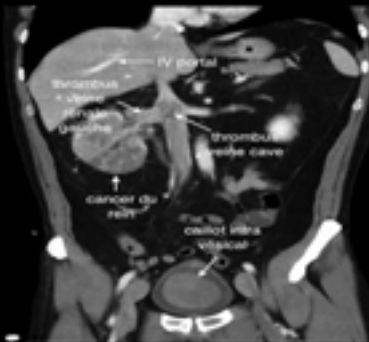



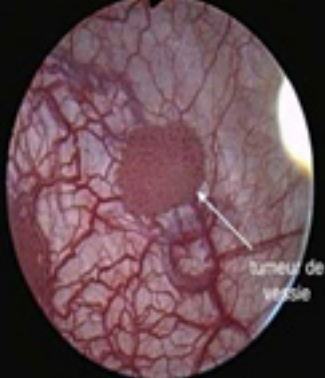
cancer
du rein

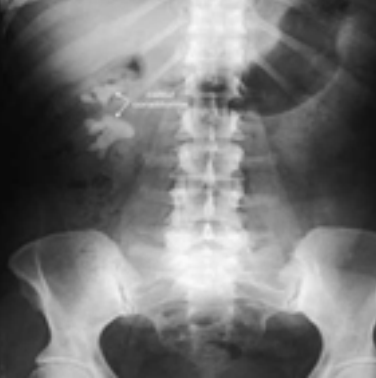néphrose
néphrose

ly adénopathie





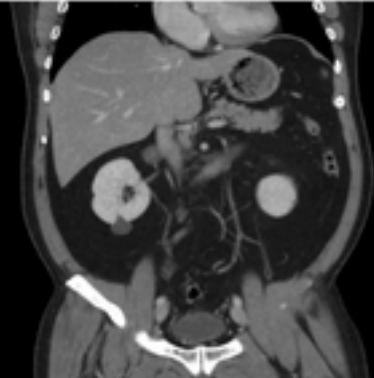tumeur de
vessie

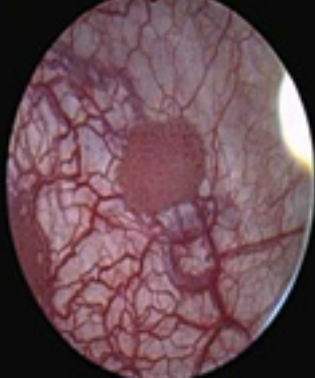


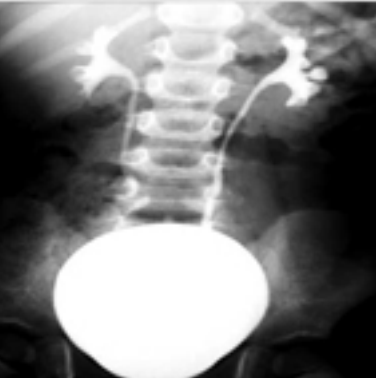oedème du gland
et du prépuce

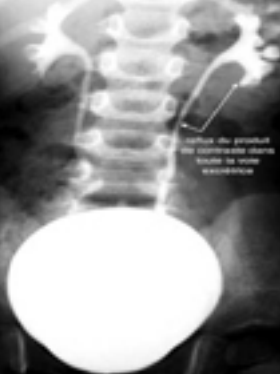

anneau prépuce
de striction









iv portal

krusta renal
bostniak 1

